

*Department of  
Radiology  
Techniques  
The Second Stage*



# *Forearm And Types of Fractures*

## *Lecture 3*

*Assist. Lecturer*

*Tariq Nadhim Jassim*

*Fadhil Aad Leftah Al-zurfi*

# *Basic Projections of Forearm*

## *Two Positions*

*1- Anterior - Posterior (AP)*

*2- Lateral*

*Cassette Out Bucky .*

*24 x 30-cm (10x12 inches)*

Carpal Bones

Styloid Process

Ulna Head

Styloid Process

Ulna

Radius

Radial Tubercle

Radial Neck

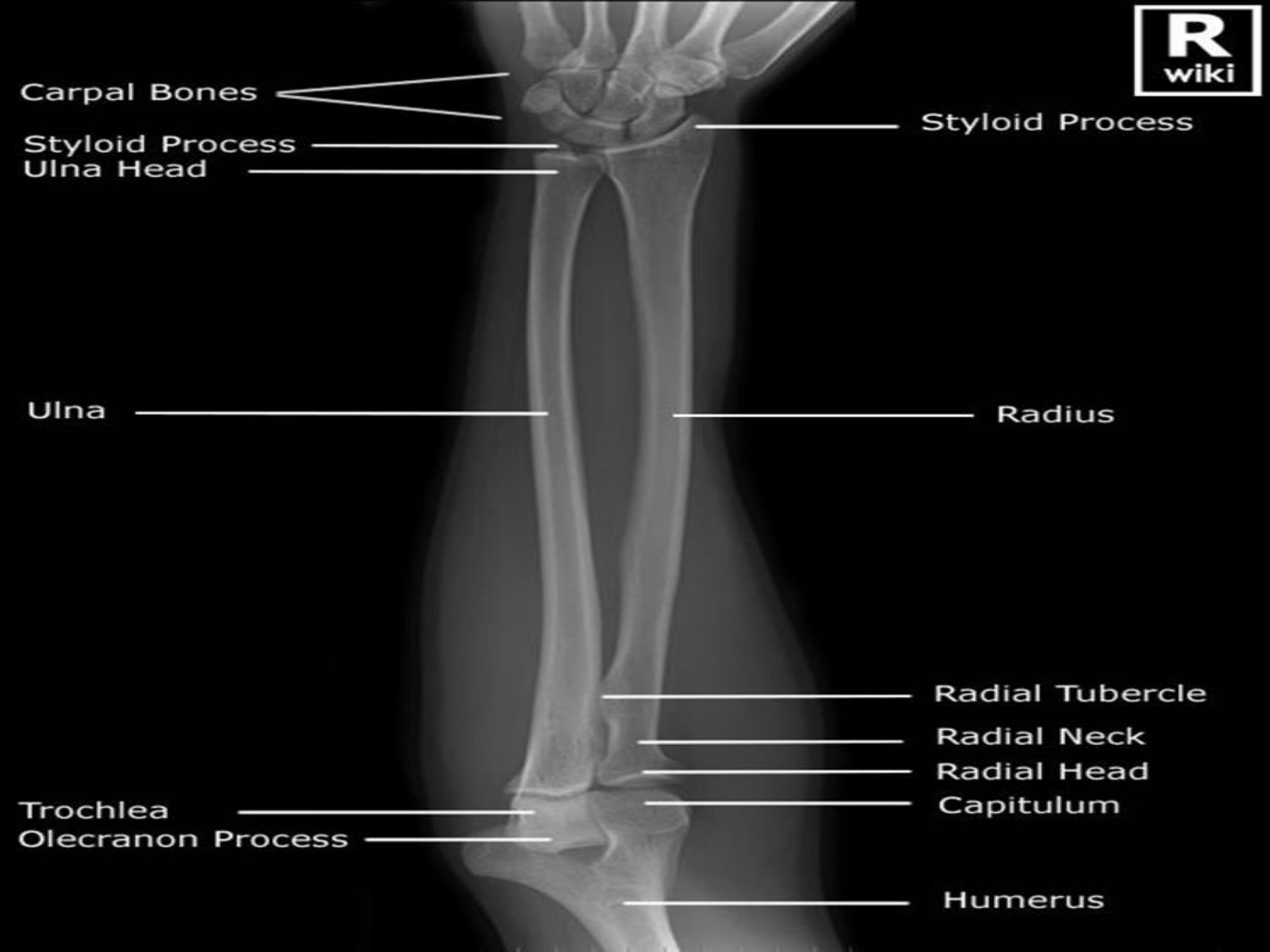
Radial Head

Capitulum

Humerus

Trochlea

Olecranon Process



# ***1- Anterior - Posterior (AP)***

## ***Position of Patient***

- The patient is seated alongside the table, with the affected side nearest to the table.
- The arm is abducted and the elbow joint is fully extended, with the supinated forearm resting on the table.
- The shoulder is lowered to the same level as the elbow joint.
- The arm is adjusted such that the radial and ulnar styloid processes and the medial and lateral epicondyles are equidistant from the cassette.
- The lower end of the humerus and the hand are immobilized using sandbags

## ***Direction and centering of the X-ray beam***

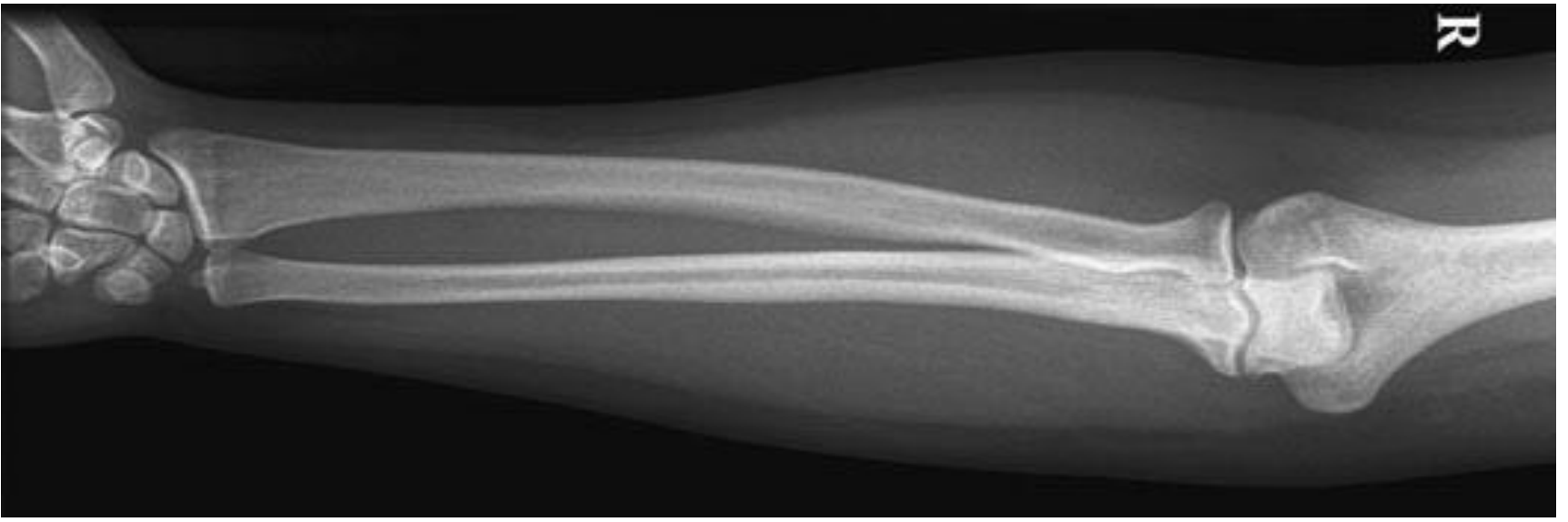
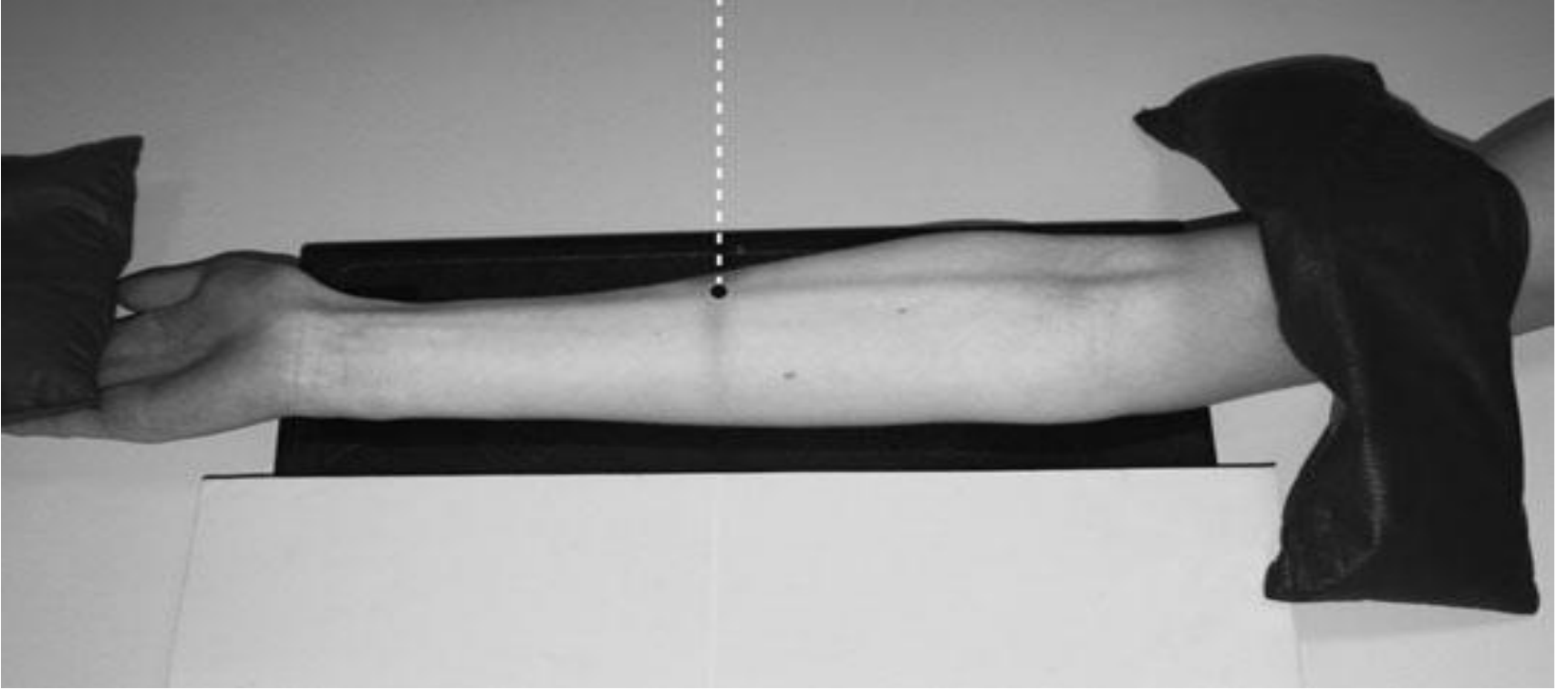
- The vertical central ray is centered in **the midline of the forearm to a point midway between the wrist and elbow joints.**

## ***Essential image characteristics***

- Both joints elbow and the wrist should be seen in the true antero-posterior position, with the radial and ulnar styloid processes and the epicondyles of the humerus equidistant from the cassette.

## ***Note***

The postero-anterior projection of the forearm with the wrist pronated is not satisfactory because, in this projection, the radius is superimposed over the ulna for part of its length



## ***2- Lateral***

### ***Position of Patient***

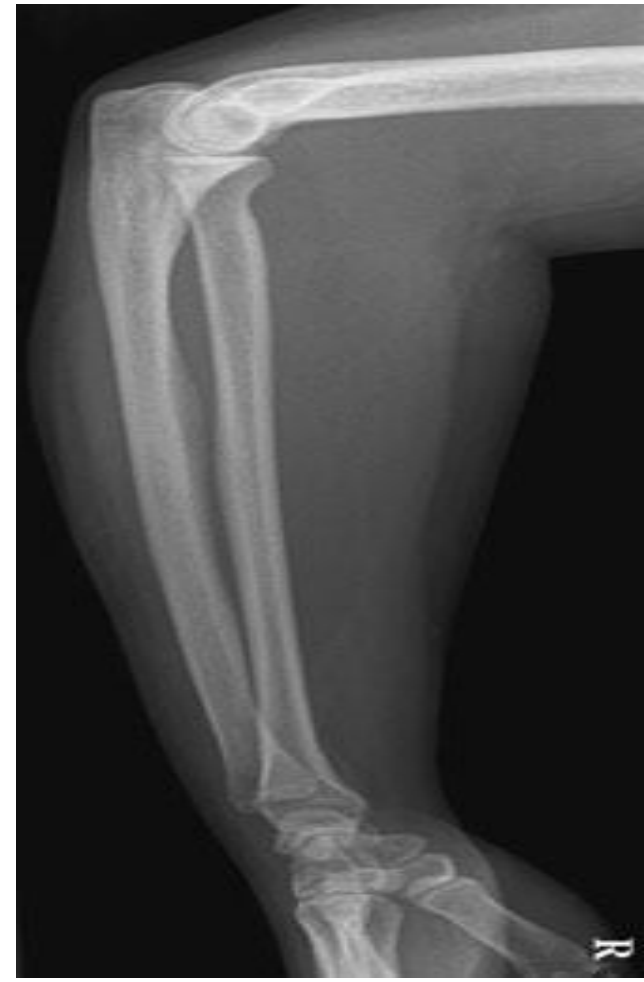- From the antero-posterior position, the elbow is flexed to 90 degrees.
- The humerus is internally rotated to 90 degrees to bring the medial aspect of the upper arm, elbow, forearm, wrist and hand into contact with the table.
- The cassette is placed under the forearm to include the wrist joint and the elbow joint.
- The arm is adjusted such that the radial and ulnar styloid processes and the medial and lateral epicondyles are superimposed.
- The lower end of the humerus and the hand are immobilized using sandbags.

### ***Direction and Centering of the X-ray beam***

- The vertical central ray is centred in **the midline of the forearm to a point midway between the wrist and elbow joints.**

# ***Essential Image Characteristics***

- Both the elbow and the wrist joint must be demonstrated on the image.
- Both joints should be seen in the true lateral position, with the radial and ulnar styloid processes and the epicondyles of the humerus superimposed.



# ***Bone Fracture***

A bone fracture is a full or partial break in the continuity of bone tissue. Fractures can occur in any bone in the body.

## ***Types of Bone Fractures***

**Displaced Fracture:** bone breaks into two or more pieces and moves out of alignment.

**Non-Displaced Fracture:** the bone breaks but does not move out of alignment (e.g, greenstick fracture)

**Closed Fracture:** the skin is not broken.

**Open Fracture:** the bone has broken through the skin(compound or complex)  
this is a **medical emergency**. In Addition to

**1-Avulsion Fracture:** when a fragment of bone is pulled away by ligament or tendon which its attachment.

**2-Impacted Fracture:** ends are driven into each other; commonly seen in arm fractures in children.

**3-Comminuted Fracture:** the bone breaks into several pieces.

**4-Compression or Wedge Fracture:** usually involves the bones in the back (vertebrae).

**5-Greenstick Fracture:** an incomplete fracture in which the bone is bent; occurs most often in children.

**6-Linear Fracture:** the break is parallel to the bone's long axis.

**7-Oblique Fracture:** the break has a curved or sloped pattern.

**8-Pathologic Fracture:** caused by a disease that weakens the bones.

**9-Spiral Fracture:** one part of the bone has been twisted at the break point.

**10-Stress Fracture:** a hairline crack.

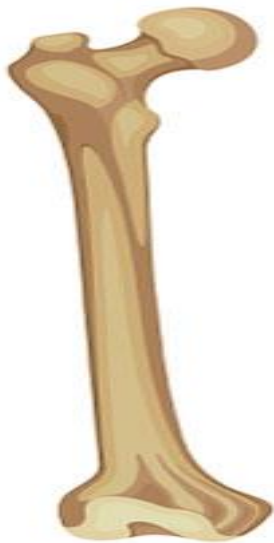**11-Transverse Fracture:** the broken piece of bone is at a right angle to the bone's axis.

**12-Epiphyseal Fracture:** a fracture through the epiphysis.

**13-Depressed Fracture:** a fracture in which fragments are driven inward  
(skull and facial fracture)

**14-Segmental Fracture:** The same bone is fractured in two places, segment of bone between the two breaks.

# TYPES OF BONE FRACTURES



**Open**



**Transverse**



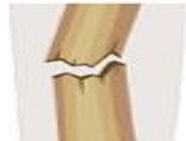**Greenstick**



**Comminuted**



**Sigmoidal**



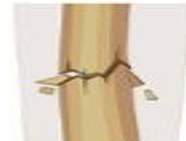**Closed**



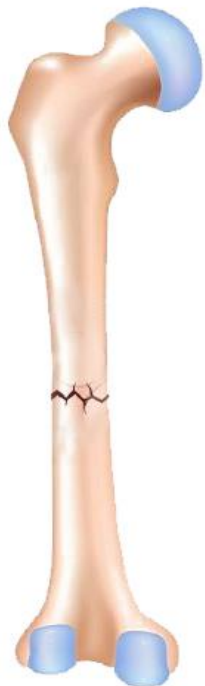**Spiral**



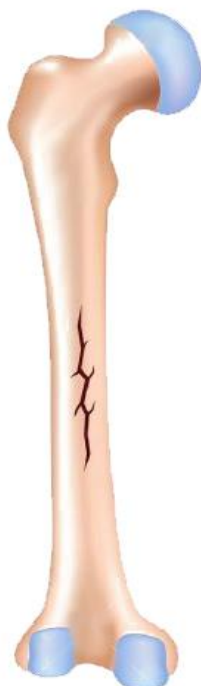**Linear**



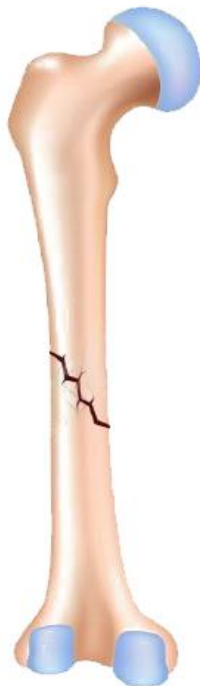**Impacted**



**Transverse**



**Linear**



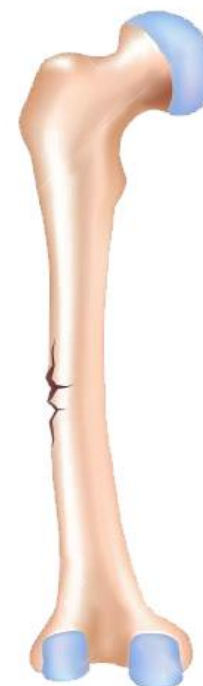**Oblique non-displaced**



**Oblique displaced**



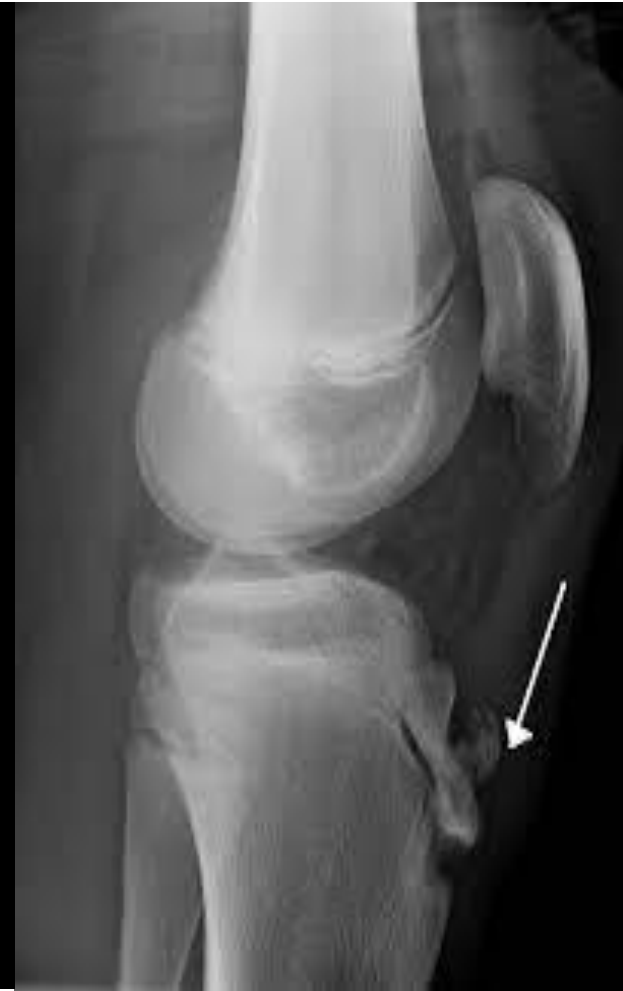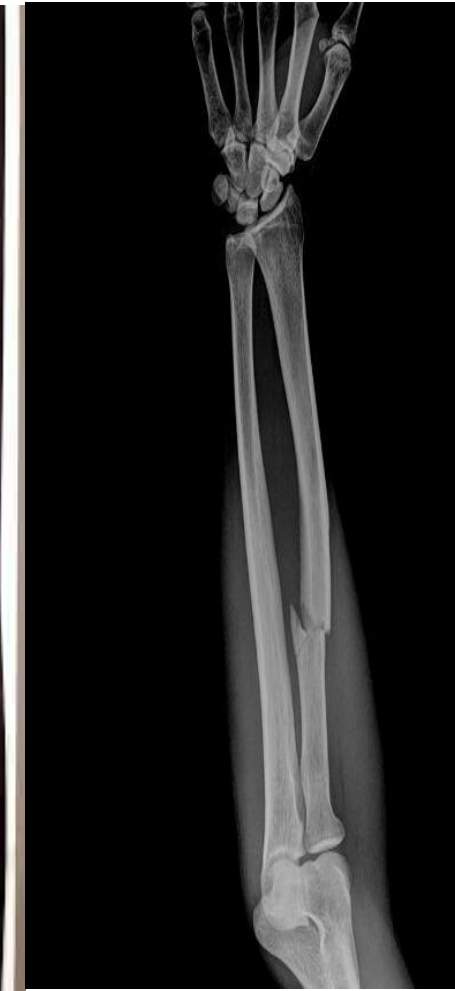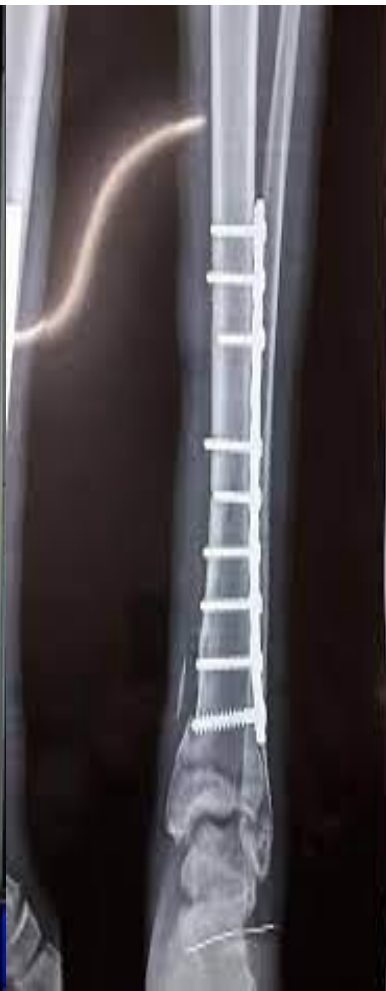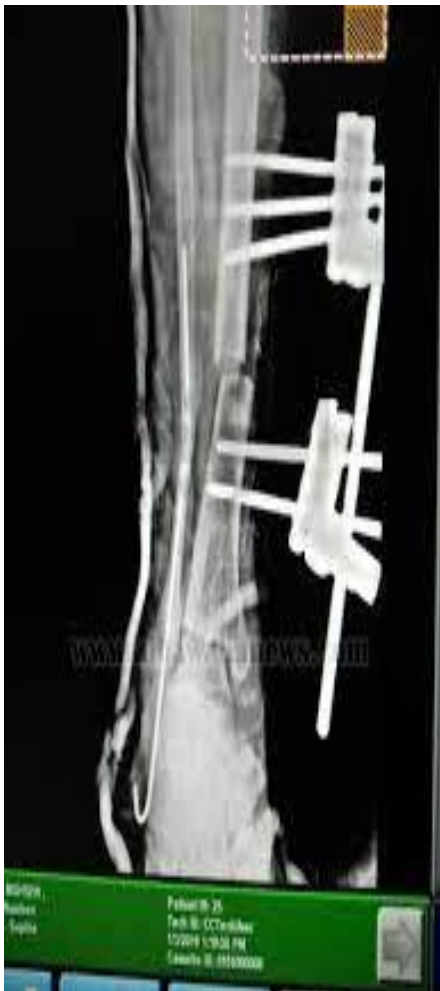**Spiral**



**Greenstick**



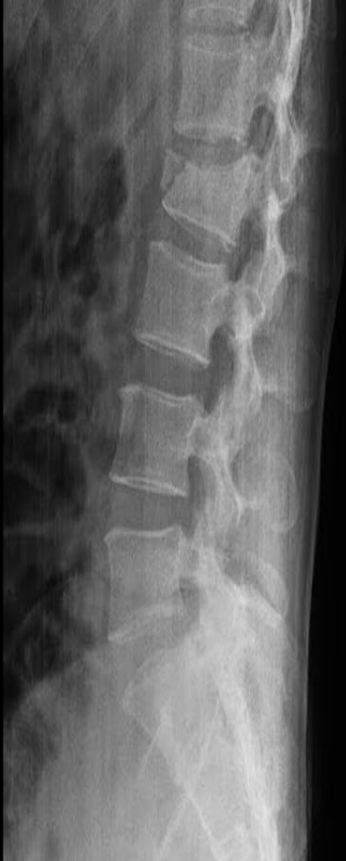**Comminuted**



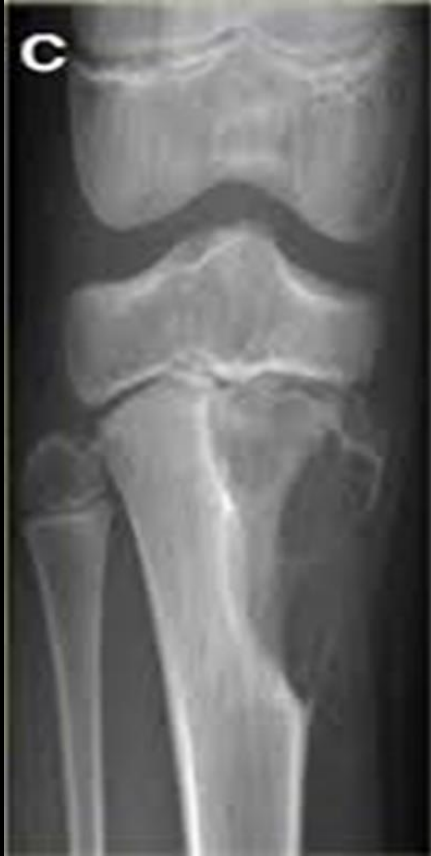**Internal Fixation External Fixation**

***Oblique* Fracture**

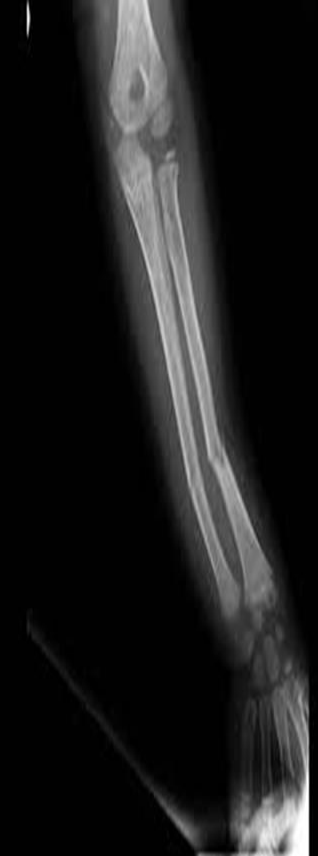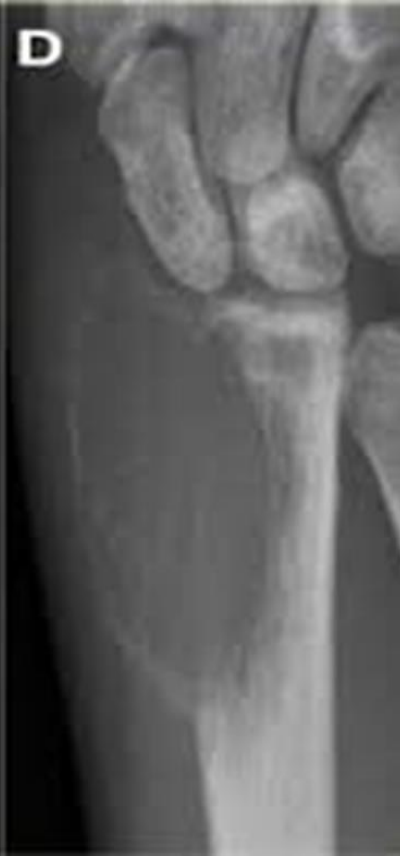**Avulsion Fracture**



**Wedge Fracture**



**Pathologic Fracture**



**Greenstick Fracture**

Thanks

